

## A Simple and Fast Algorithm to Detect Blood Vessels in Fundus Retinal Image

Prithivirajan<sup>1</sup>, T.Nedunchezian<sup>2</sup> and B. Justis Rabi<sup>3</sup>

<sup>1</sup> Dept. of Computer Science and Engineering, Sri Andal Alagar College of Engineering, Chennai, India.

<sup>2</sup> Dept. of Computer Science and Engineering, Sri Andal Alagar College of Engineering, Chennai, India.

<sup>3</sup> Dept. of Electrical and Electronics Engineering, Sri Andal Alagar College of Engineering, Chennai, India.

prithiviraj75@gmail.com.

Received 16 February 2015 / Accepted 10 April 2015

*Abstract- Automated fundus image analysis plays an important role in the computer aided diagnosis of ophthalmologic disorders. A lot of eye disorders, as well as cardiovascular disorders, are known to be related with retinal vasculature changes. Many studies have been done to explore these relationships. Fovea is a part of the eye, located in the center of the macula region of the retina. The fovea is responsible for sharp central vision, which is necessary in humans for reading, driving, and any activity where visual detail is of primary importance. In this project, I have localized the blood vessels around the macular region. I have used a little bit information of optic disc and the blood vessels structure information around the macular region. The algorithm consists of two parts. In first part, I have detected the blood vessels of the retinal fundus image. In the next stage, I have utilized the geometrical distance between optic disc and fovea region and the structure of the blood vessels to perfectly localize the fovea region.*

### I. INTRODUCTION

Vision is regarded as the most precious of our senses and also the most complex. When studying vision, several different fields of science will be involved, ranging from physics to brain physiology. Macula is the specialized region of the retina responsible for high-resolution vision. It is anatomically defined as the “portion of the posterior retina that contains xanthophylls and two or more layers of ganglion cells”. This roughly circular area is about 5-6 mm in diameter and corresponds to approximately 15-20° of the visual field (VF). The central part of the macula, called the fovea, is typically more pigmented than the surrounding tissue and has a diameter of about 1.5-2.0 mm. In the parafovea, just outside the fovea, the retina is thickest because of multiple layers of ganglion cell. In this area, the light does not need to pass through any other retinal cell layers or blood vessels, which otherwise might absorb or scatter the incoming light. The foveola is the most central part of the fovea, with a diameter of approximately 0.3 mm or 1° VF, and is entirely composed by cones.

### II. METHODOLOGY

In this chapter, the stages involved in the detection of fovea region in fundus retinal image are discussed. It starts with a brief review of the block diagram processes involved.

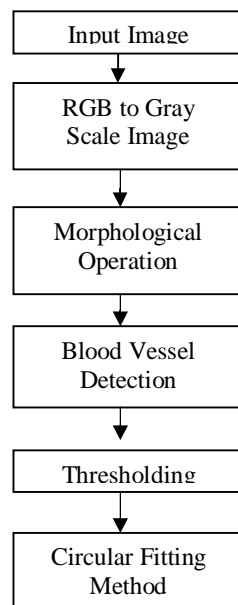


Fig. 1. Block Diagram Representation

### **RGB TO GRAY SCALE IMAGE**

Humans perceive color through wavelength-sensitive sensory cells called cones. There are three different types of cones, each with a different sensitivity to electromagnetic radiation (light) of different wavelength.

Syntax:  $I = \text{rgb2gray}(\text{RGB})$ . It converts the true color image RGB to the grayscale intensity image I. `rgb2gray` converts RGB images to grayscale by eliminating the hue and saturation information while retaining the luminance.

### **MORPHOLOGICAL OPERATION**

Morphology is a broad set of image processing operations that process images based on shapes. Morphological operations apply a structuring element to an input image, creating an output image of the same size. In a morphological operation, the value of each pixel in the output image is based on a comparison of the corresponding pixel in the input image with its neighbors. By choosing the size and shape of the neighborhood, you can construct a morphological operation that is sensitive to specific shapes in the input image.

**Structural Element** : An essential part of the dilation and erosion operations is the structuring element used to probe the input image. A structuring element is a matrix consisting of only 0's and 1's that can have any arbitrary shape and size. The pixels with values of 1 define the neighborhood.

**Dilation**: Dilation adds pixels to the boundaries of objects in an image. The value of the output pixel is the maximum value of all the pixels in the input pixel's neighborhood.

$$A \oplus B = \bigcup_{z \in B} A_z$$

**Erosion**: Erosion is the opposite of the dilation. The value of the output pixel is the minimum value of all the pixels in the input pixel's neighborhood. In a binary image, if any of the pixels is set to 0, the output pixel is set to 0. The Erosion of A by the structuring element B is defined by:

$$A \ominus B = \{z \in E \mid B \subseteq A\}$$

**Opening**: Opening generally smoothes the contour object, breaks narrow isthmuses, and eliminates thin protrusions.

**Closing**: Closing also tends to smooth sections of contours but, as opposed to opening, it generally fuses narrow breaks and long thin gulfs, eliminates small holes, and fills gaps in the contour. Closing also tends to smooth sections of contours.

**Blood Vessel Detection**: Blood vessels segmentation blood of the retinal images allows early diagnosis of disease; automation of this process provides various benefits including minimizing subjectivity and eliminating a painstaking, tedious task. Previous approaches require some more changes that can take the case of abnormal retinal images.

- (1) Pattern recognition techniques,
- (2) Model-based approaches,
- (3) Tracking-based approaches,
- (4) Artificial intelligence-based approaches,
- (5) Neural network-based approaches, and
- (6) Miscellaneous tube-like object detection approaches.

**THRESHOLDING**: Thresholding is one of the most important approaches to image segmentation. From a grayscale image, thresholding can be used to create binary images. Segmentation is categorized as

- 1) Threshold based segmentation,
- 2) Edge based segmentation,
- 3) Region based segmentation,
  - 4) Clustering techniques,
  - 5) Matching.

### **III. RESULTS AND CONCLUSION**

**Input Image** : The normal fundus image is taken as input image with resolution of 565X584 pixels in Tagged Image File Format (.tif). In here we are converting input image to gray scale image as shown in fig. 3.

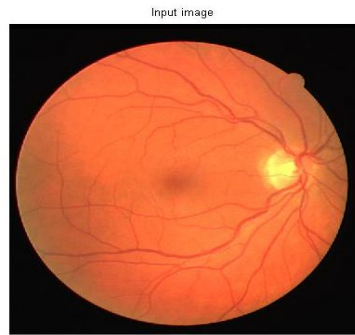


Fig. 2. Input fundus images

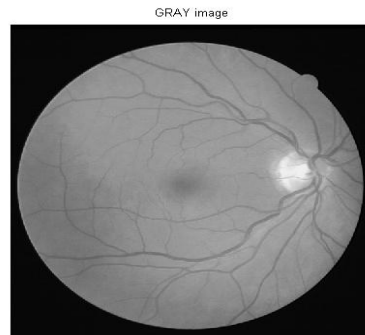

Fig. 3. Grayscale Image

**Morphological Operation:** Morphological operation like opening and closing performed on the grayscale image as shown in below figures 4 and 5.

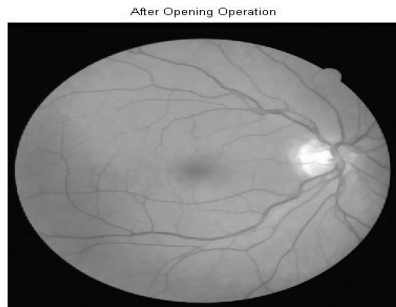

Fig. 4. Morphological Opening Operation

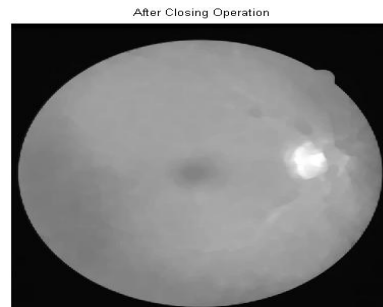

Fig. 5. Morphological Closing Operation

**Blood Vessel Detection and Thresholding**

Blood vessel image as shown in fig 4.5 and Thresholding the blood vessel detected image as shown in fig 6.

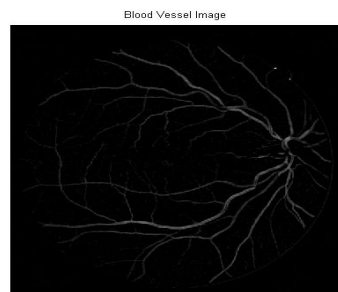


Fig. 6. Blood Vessel Detected Image

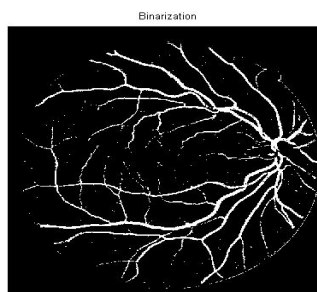


Fig. 7. Threshold Image

**Blood Vessel Detected Image and Masking:** Inverting the pixel values of threshold image and creating mask and placing on image. Placing mask represents the final output stage

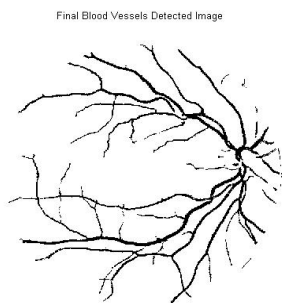


Fig. 8. Final Blood Vessel

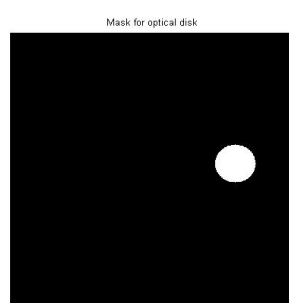


Fig. 9. Creating Mask Detected Image

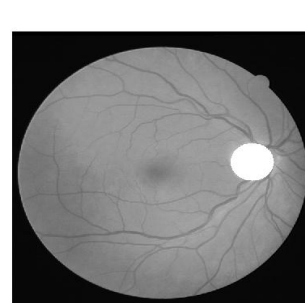

Fig. 10. Placing Mask Image Image

## CONCLUSION

In this paper, we have described a new efficient method to localize the fovea in retinal fundus image. We have used some morphological operators and geometrical features to localize the fovea region successfully. Experiment shows that the outcome the scheme is comparable with others when applied on standard data set. Moreover, it performs well on our own data set consisting of images with variation.

## REFERENCES

1. Al-Diri. B, A. Hunter, and D. Steel, "An active contour model for segmenting and measuring retinal vessels," IEEE Transactions on Medical Imaging, vol. 24, no. 9, pp. 1488–1497, 2014.
2. Chutatape. O, "Fundus foveal localization based on vessel model," in Proceedings of the 28th IEEE EMBS Annual International Conference New York City, USA, 2012, pp. 4440–4444.
3. Foracchia. M, E. Grisan, and A. Ruggeri, "Detection of optic disc in retinal images by means of a geometrical model of vessel structure," IEEE Transactions on Medical Imaging, vol. 23, no. 10, pp. 1189–1195, 2010.
4. Sekhar. S, W. Al-Nuaimy, and A. K. Nandi, "Automated localization of optic disk and fovea in retinal fundus images," in 16th European Signal Processing Conference (EUSIPCO 2008), Lausanne, Switzerland. EURASIP, August 25-29, 2008.
5. Staal. J, M. D. Abramoff, M. Niemeijer, M. A. Viergever, and B. van Ginneken, "Ridge-based vessel segmentation in color images of the retina," IEEE Transactions on Medical Imaging, vol. 23, no. 4, pp. 501– 509, 2004.
6. Youssif, A. Z. Ghalwash, and A. A. S. A.-R.Ghoneim, "Optic disc detection from normalized digital fundus images by means of a vessel direction matched filter," IEEE Transactions on Medical Imaging, vol. 27, no. 1, pp. 11–18, 2008.
7. T. R. Ganesh Babua<sup>1</sup>, S. Shenbaga Devib<sup>2</sup>, R. Venkateshc<sup>3</sup> "Optic nerve head segmentation using fundus images and optical coherencetomography images for glaucoma detection" Biomed Pap, 2015 Dec.
8. T. R. Ganesh Babua<sup>1</sup>, R.Sathishkumar<sup>2</sup>, and Rengarajvenkatesh<sup>3</sup>, " Segmentation of Optic Nerve Head for Glaucoma Detection using Fundus images" Vol. 7(2), 2014.
9. Cemal kose<sup>1</sup> and Cevat Ikibas<sup>2</sup>, "Statistical Techniques for Detection of Optic Disc and Macula and Parameters Measurement in Retinal Fundus Images" Vol31 (6):395-404, 2010.
10. C. Sinthanayothin, J. F. Boyce, H. L. Cook and T. H. Williamson, "Automated location of the optic disc, fovea and retinal blood vessels from digital colour fundus images," Brit. J. Ophthalmol., 83: 902-910, 1999.
11. H. Narasimha-Iyer, J.M. Beach, B. Khoobehi and B. Roysam, "Automatic identification of retinal arteries and veins from dual-wavelength images using structural and functional features," IEEE Trans. Biomed. Eng., 54: 1427-1435, 2007.